

Management of Extrapleural hematoma

2024. 05. 31. | 국립중앙의료원 | 서울권역외상센터 | 김영웅



Extrapleural hematoma (EPH)

- Accumulation of blood in the extrapleural space
 - Between the parietal pleura and the endothoracic fascia (m/c)
- Relatively rare and under-reported condition
- Journal of Chest Surgery: 1 case
 - Park Y, Lee J, Lee DG. Traumatic Extrapleural Hematoma Mimicking a Hemothorax. J Chest Surg 2010;43:328-331.



Extrapleural hematoma (EPH)

- Three groups
 - Spontaneous: Ruptured thoracic aortic aneurysm
 - Iatrogenic: Central line insertion or chest tube misplacement
 - **Traumatic: Blunt trauma**



Traumatic EPH

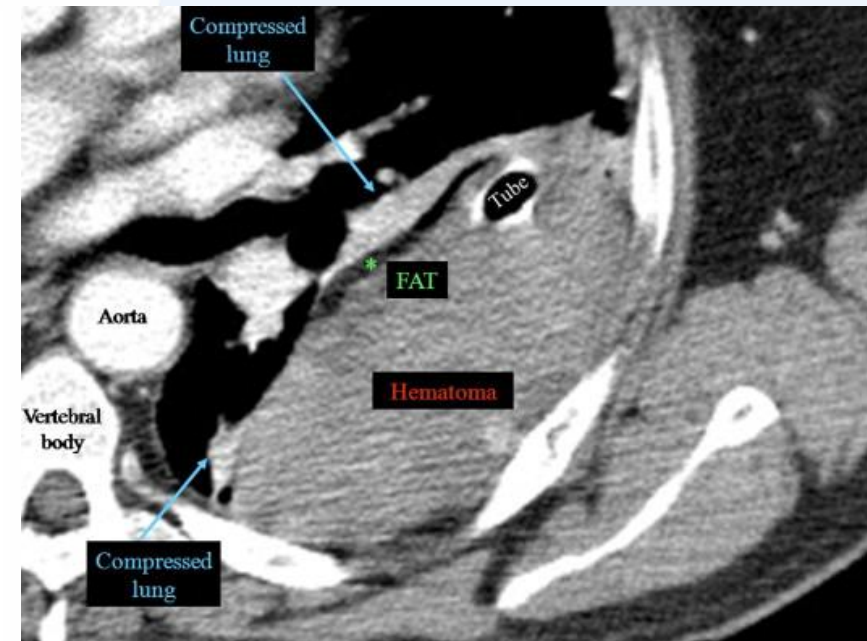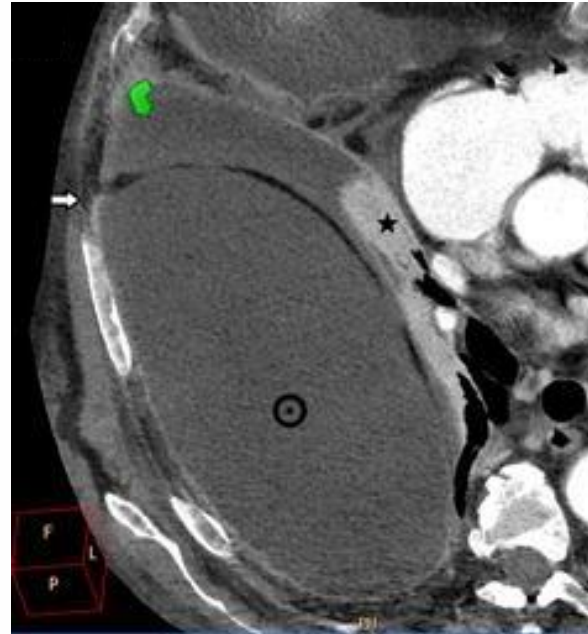
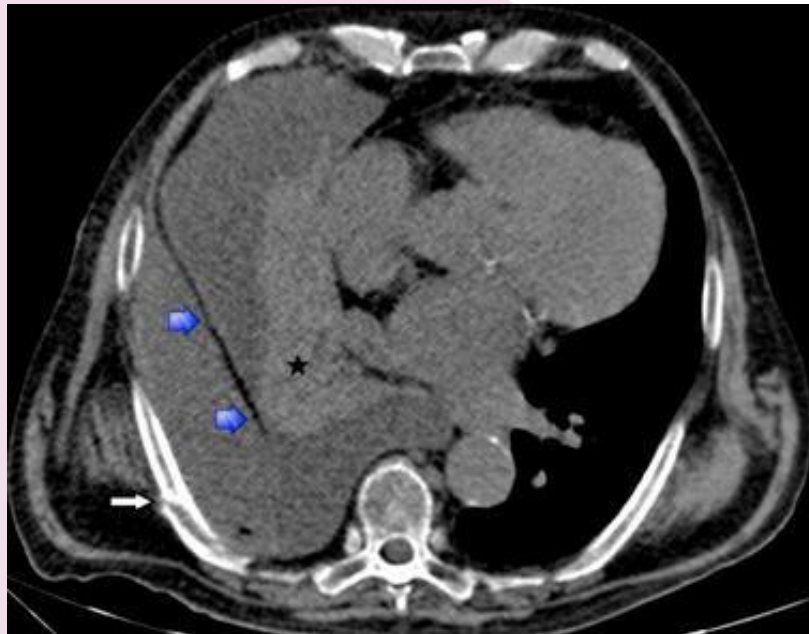
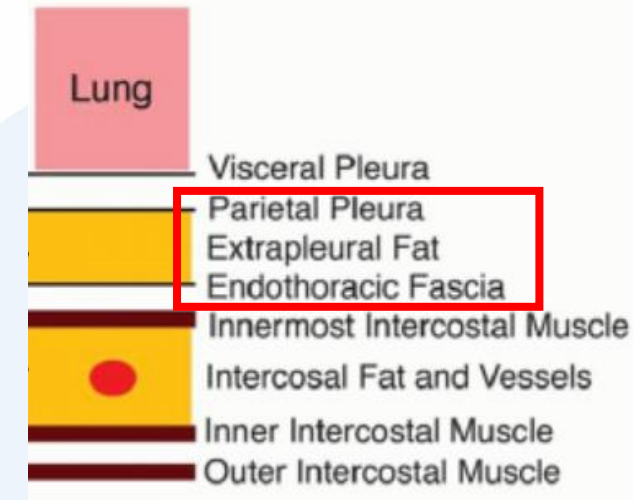
- Incidence in thoracic trauma: 7.1%*
 - Associated rib fractures: 88.2%*
 - Symptom
 - Respiratory insufficiency
 - Hypotension
 - Anemia
- Potentially life-threatening condition
- Early identification and proper management

* Rashid MA, Wikström T, Ortenwall P. Nomenclature, classification, and significance of traumatic extrapleural hematoma. J Trauma. 2000 Aug;49(2):286-90.

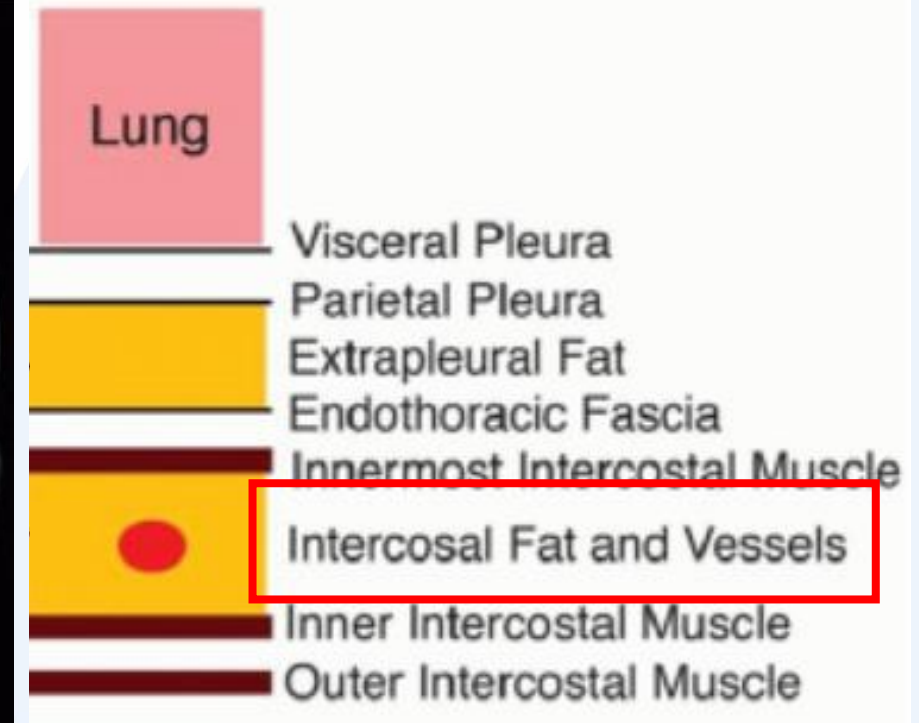
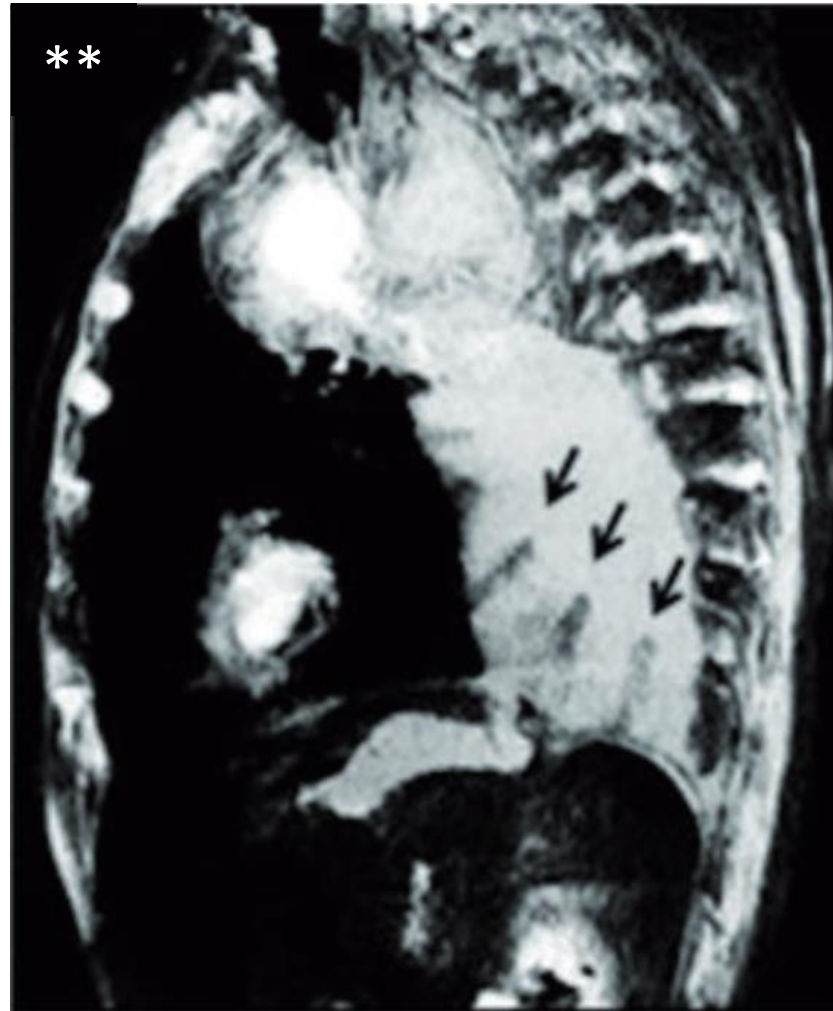
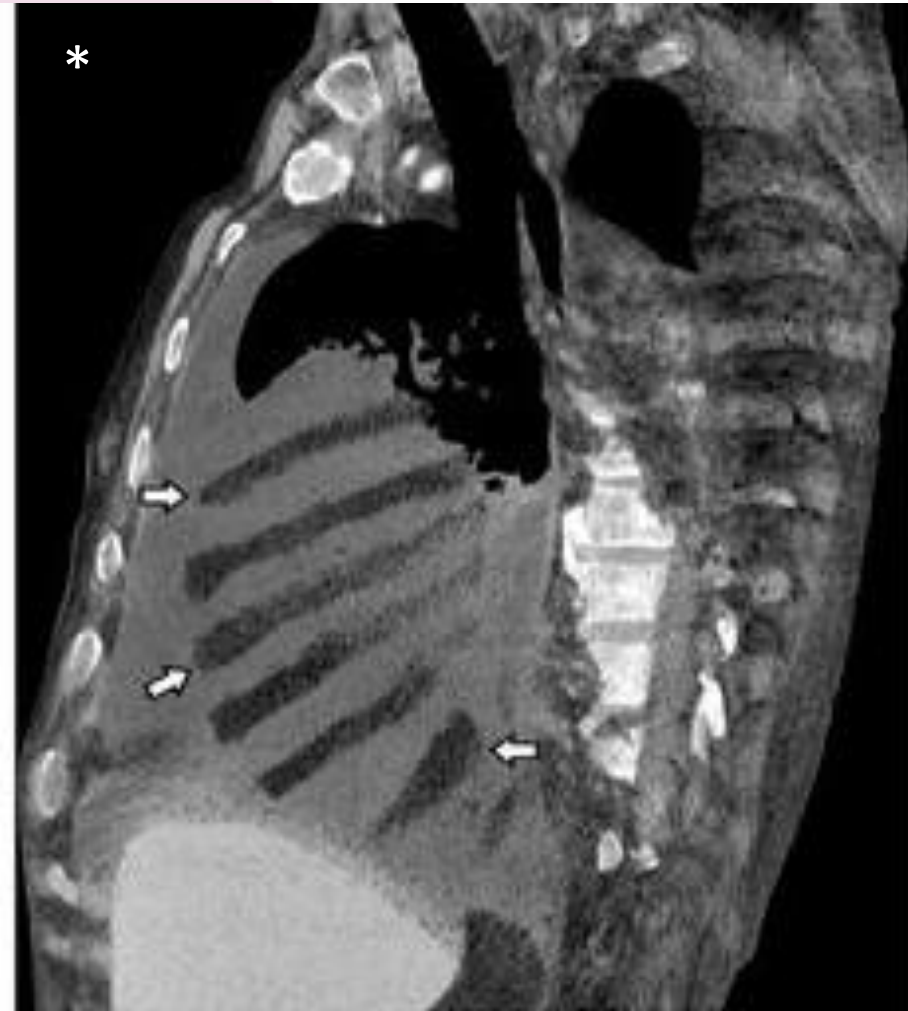

Extrapleural fat sign

- Separation of parietal pleura from endothoracic fascia
- Medial translocation, and fluid accumulation



Fat ghost rib sign



* Valente, T., Tortora, G., Bocchini, G. et al. MDCT and US of intrathoracic extrapleural space soft tissue-containing lesions: US extrapleural fat sign and MDCT fat ghost ribs sign. Radiol med 122, 479–486 (2017).

** Sica G, Dialeto G. et al. First MDCT evidence of ruptured aberrant left subclavian artery aneurysm in right aortic arch, Kommerell's diverticulum and extrapleural hematoma treated by emergency thoracic endovascular aortic repair. Monaldi Arch Chest Dis. 2020 Sep 29;90(4).

Management of EPH

- Non-operative
 - Small EPH with few clinical symptoms
→ Observation or Intervention
- Operative
 - Huge, causing circulatory and ventilatory disturbances
 - Active bleeding with unstable condition
→ Thoracotomy or VATS



Surgical approach

- Thoracotomy ¹

- Extrapleural area cannot be imaged clearly by VATS due to the absence of anatomical cavity

- VATS ^{2, 3}

- Appropriate method to
- Evacuate the hematoma

- Hybrid ⁴

- Use of thoracoscopy ur
- Useful option for surgic



the bleeding center

the active bleeding point

1 Rashid MA, Wikström T, Ortenwall P. Nomenclature, classification, and significance of traumatic extrapleural hematoma. J Trauma 2000;49:286–90.

2 Goh BK, Koong HN. Massive traumatic extrapleural hematoma mimicking hemothorax: a potential pitfall of penetrating chest trauma. J Trauma 2006;61:995–7.

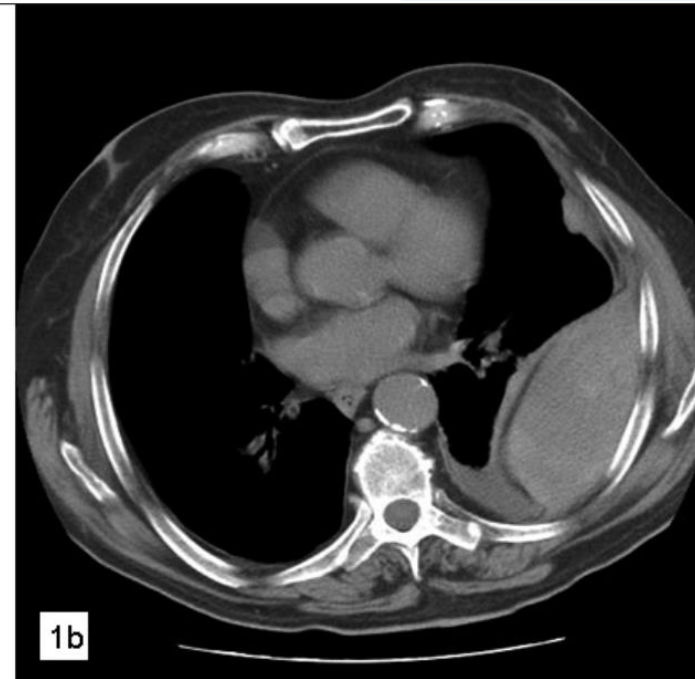
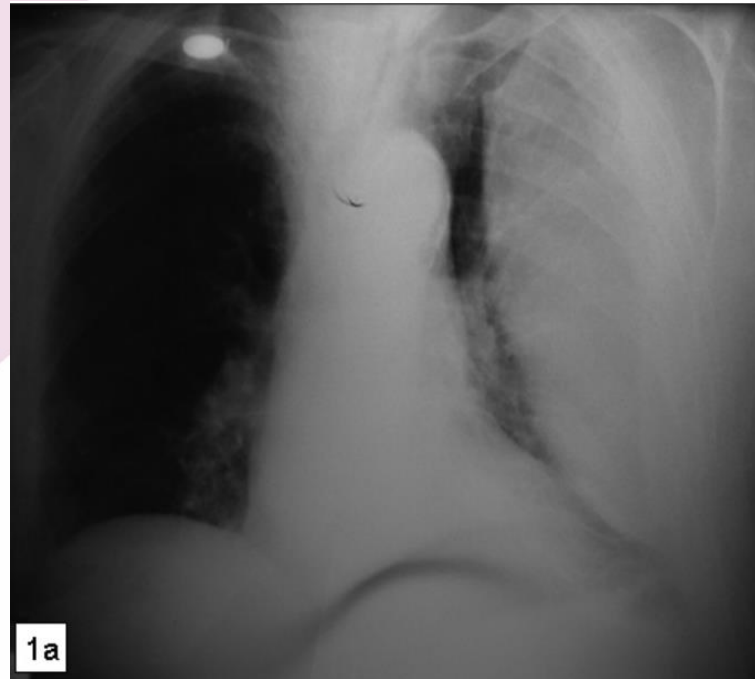
3 Poyraz AS, Kilic D, Gultekin B, Ozulku M, Hatipoglu A. Extrapleural hematoma: when is surgery indicated? Monaldi Arch Chest Dis 2005;63:166–9.

4 Igai H, Okumura N, Ohata K, Matsuoka T, Kameyama K, Nakagawa T. Rapidly expanding extrapleural hematoma. Gen Thorac Cardiovasc Surg. 2008



Case #1

- Elderly man, fall down, h/o coronary artery disease
- Initial conservative treatment d/t high risk of operation
 - Transfusion and anticoagulation reverse

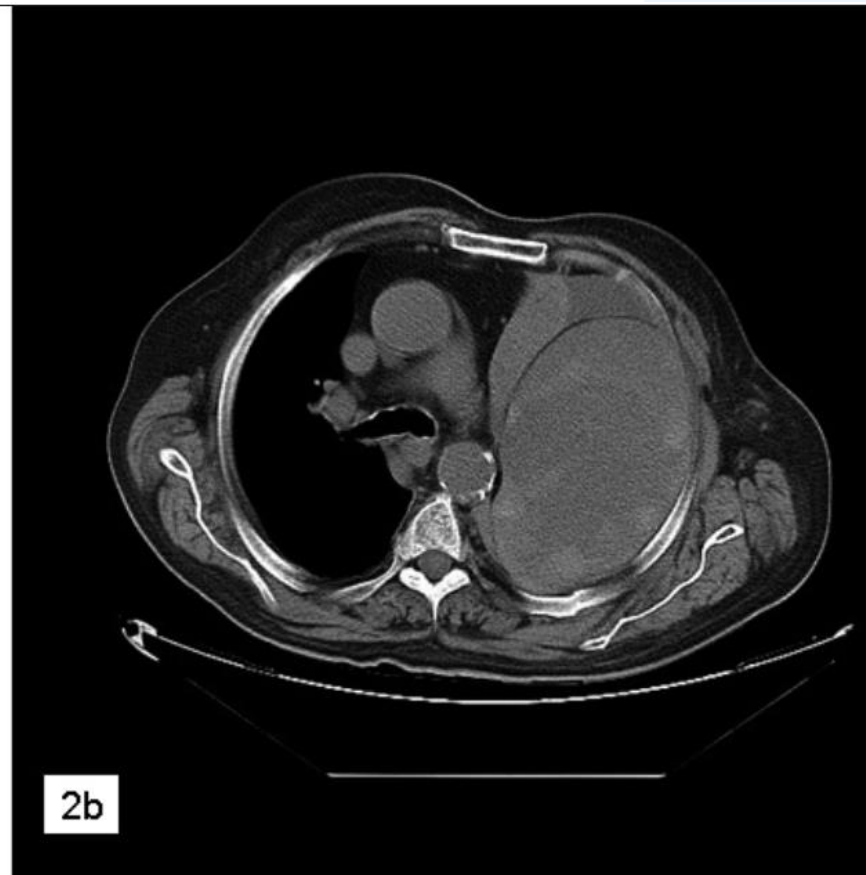
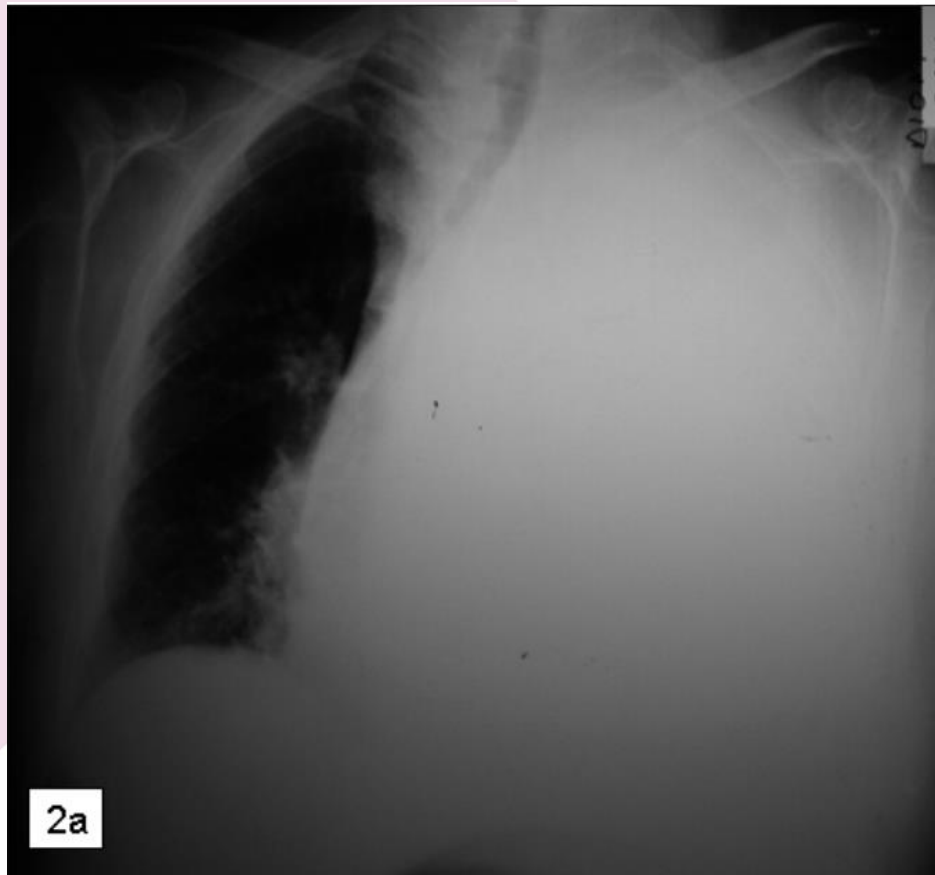


* Baikoussis NG, et al. Huge expanding extrapleural haematoma in a coronary artery disease patient: conservative or surgical treatment? Eur Rev Med Pharmacol Sci. 2011 Aug;15(8):978-9.



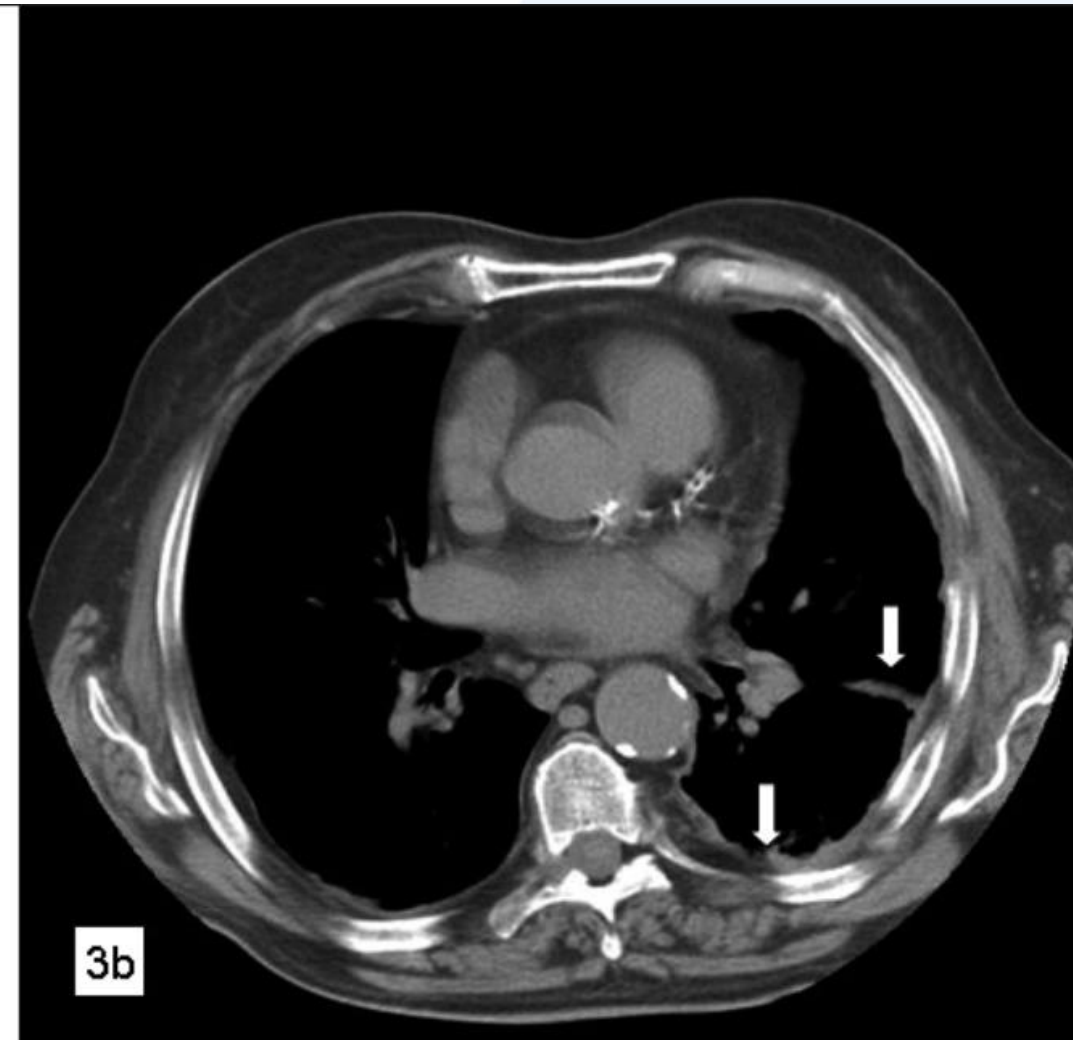
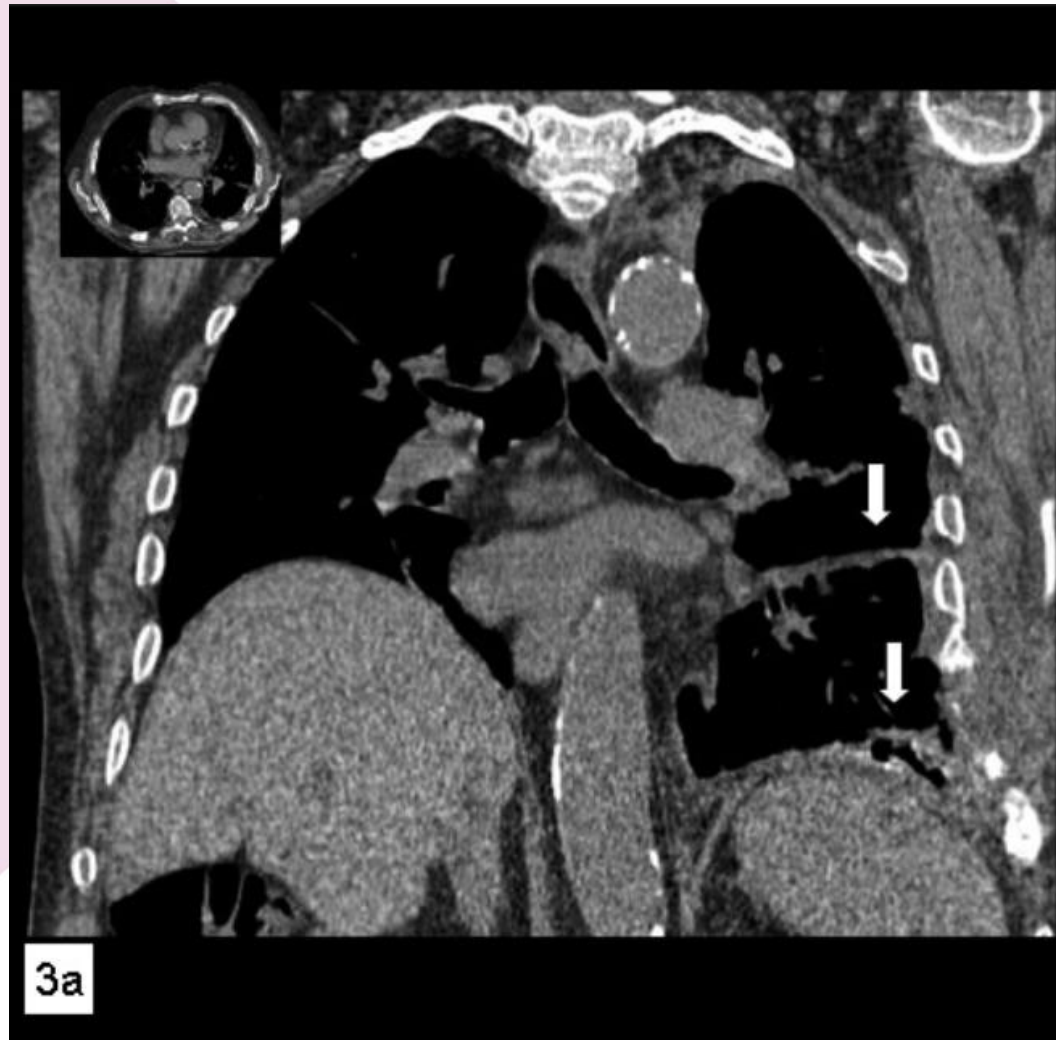
Case #1

- Hematoma expanding! (~ 48hr)
 - Cardiopulmonary disturbance
 - Surgical evacuation though left thoracotomy



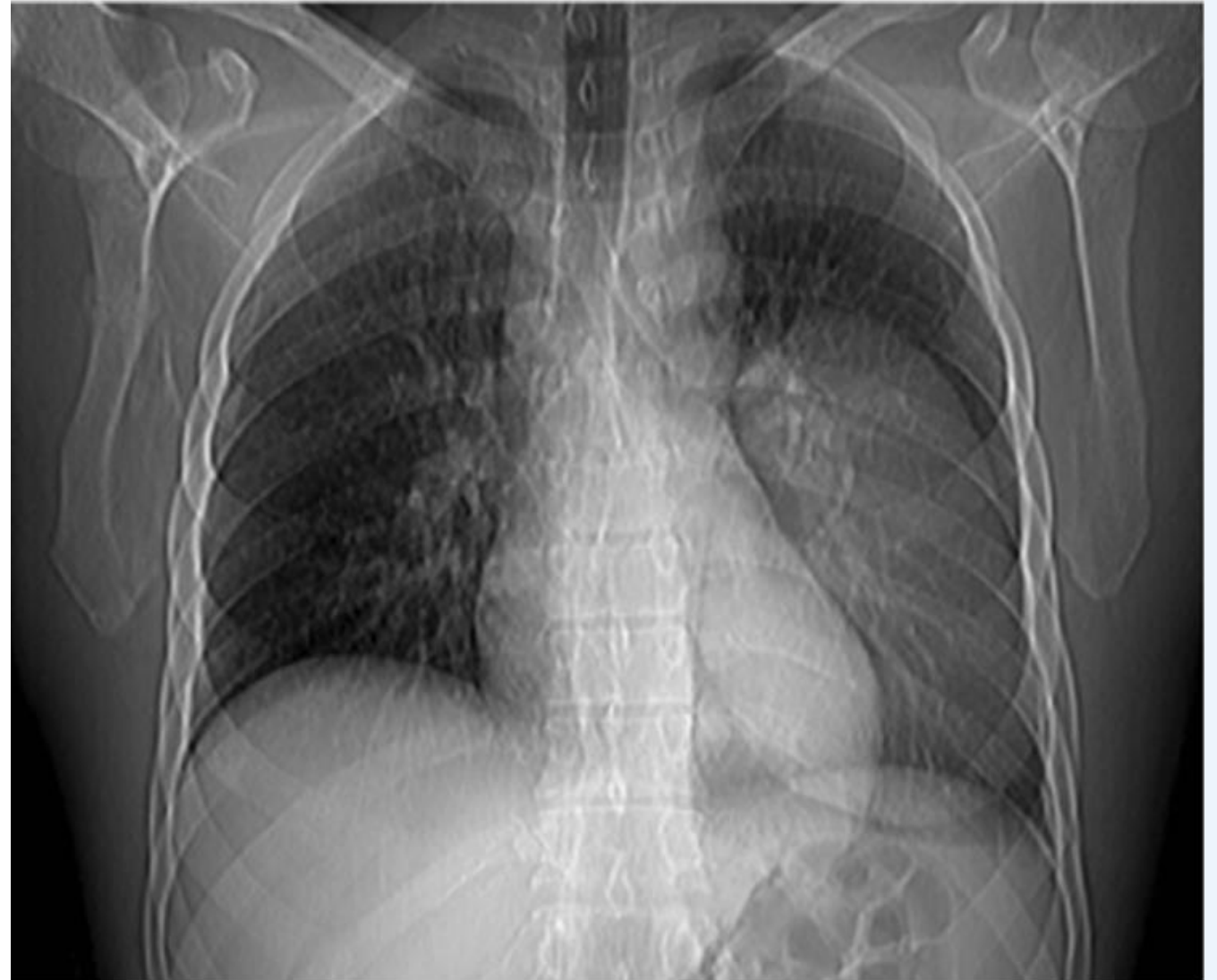Case #1

- Discharged on the POD #6



Case #2

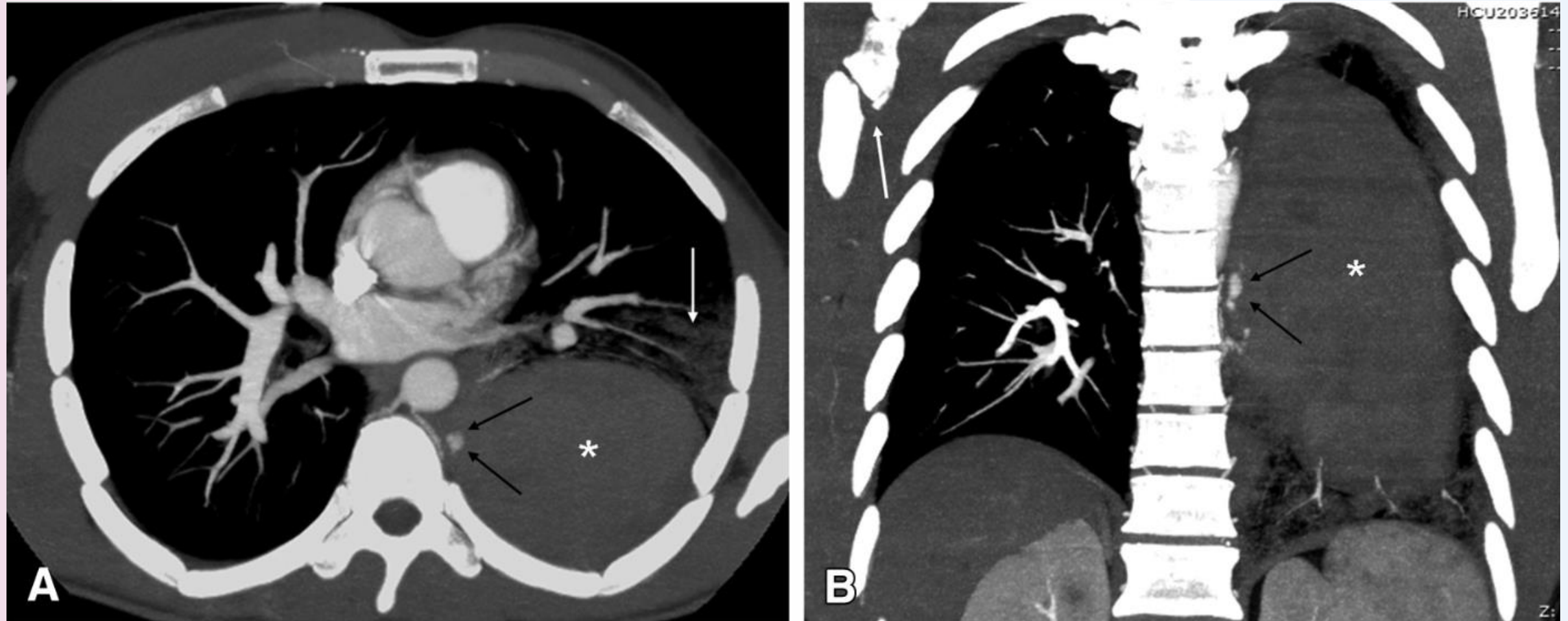
- 38y/M, 8m fall down
- Rt. scapula fx., but no rib fx.



* Gorospe L, Fernández-Méndez MÁ, et al. Nonoperative Management of a Large Extrapleural Hematoma after Blunt Chest Trauma. J Emerg Med. 2016 Aug;51(2):159-68.



Case #2

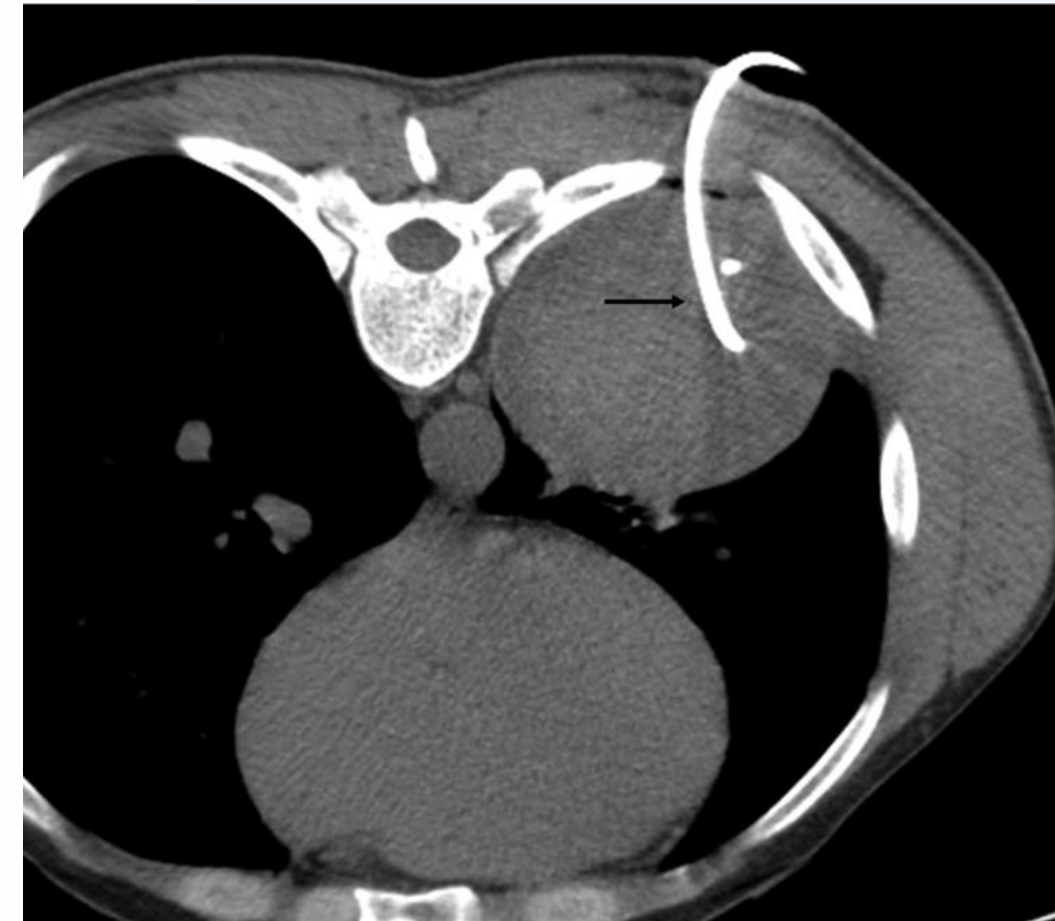

* Gorospe L, Fernández-Méndez MÁ, et al. Nonoperative Management of a Large Extrapleural Hematoma after Blunt Chest Trauma. J Emerg Med. 2016 Aug;51(2):159-63.

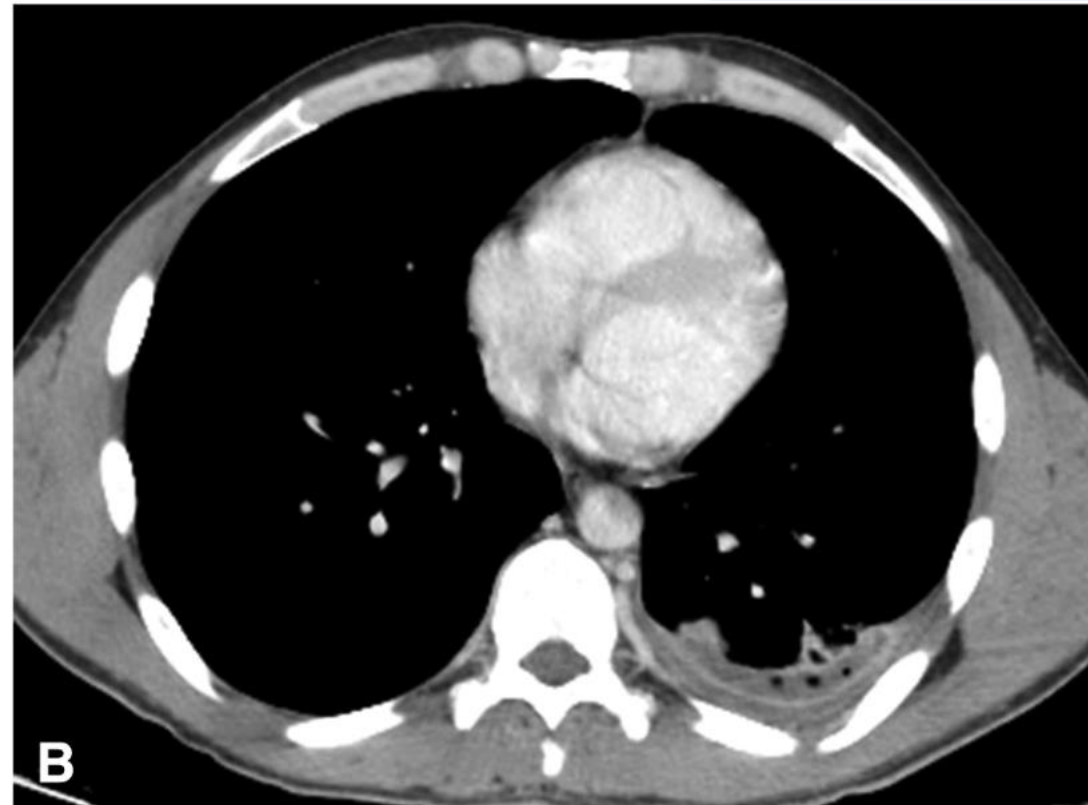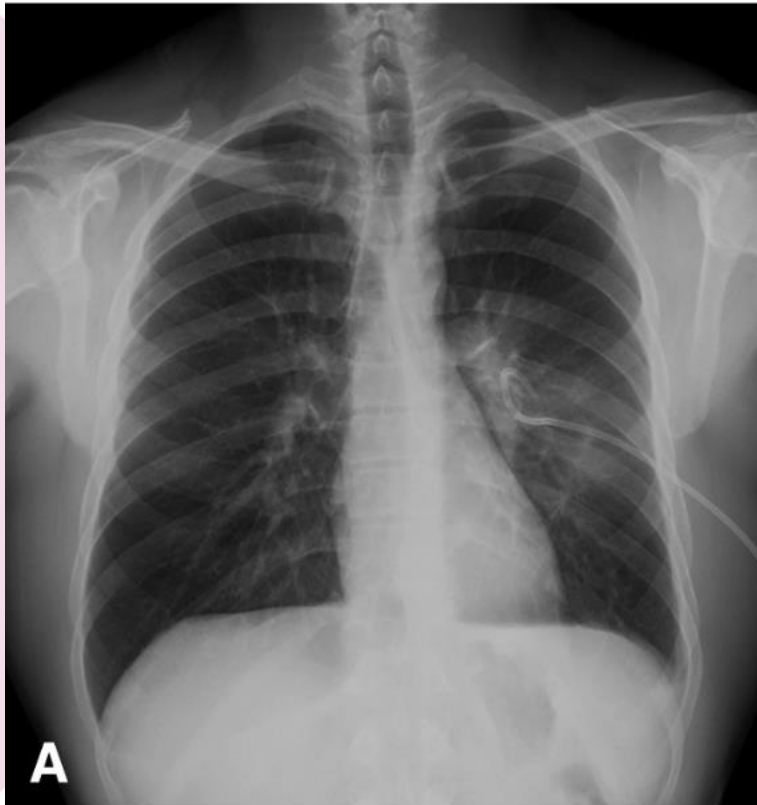


Case #2

- Angiography was immediately performed and the pseudoaneurysm was successfully embolized
- CT-guided 14Fr PCD was placed into the large EH
- Drainage of 1,400 mL



Case #2



* Gorospe L, Fernández-Méndez MÁ, et al. Nonoperative Management of a Large Extrapleural Hematoma after Blunt Chest Trauma. J Emerg Med. 2016 Aug;51(2):159-63.

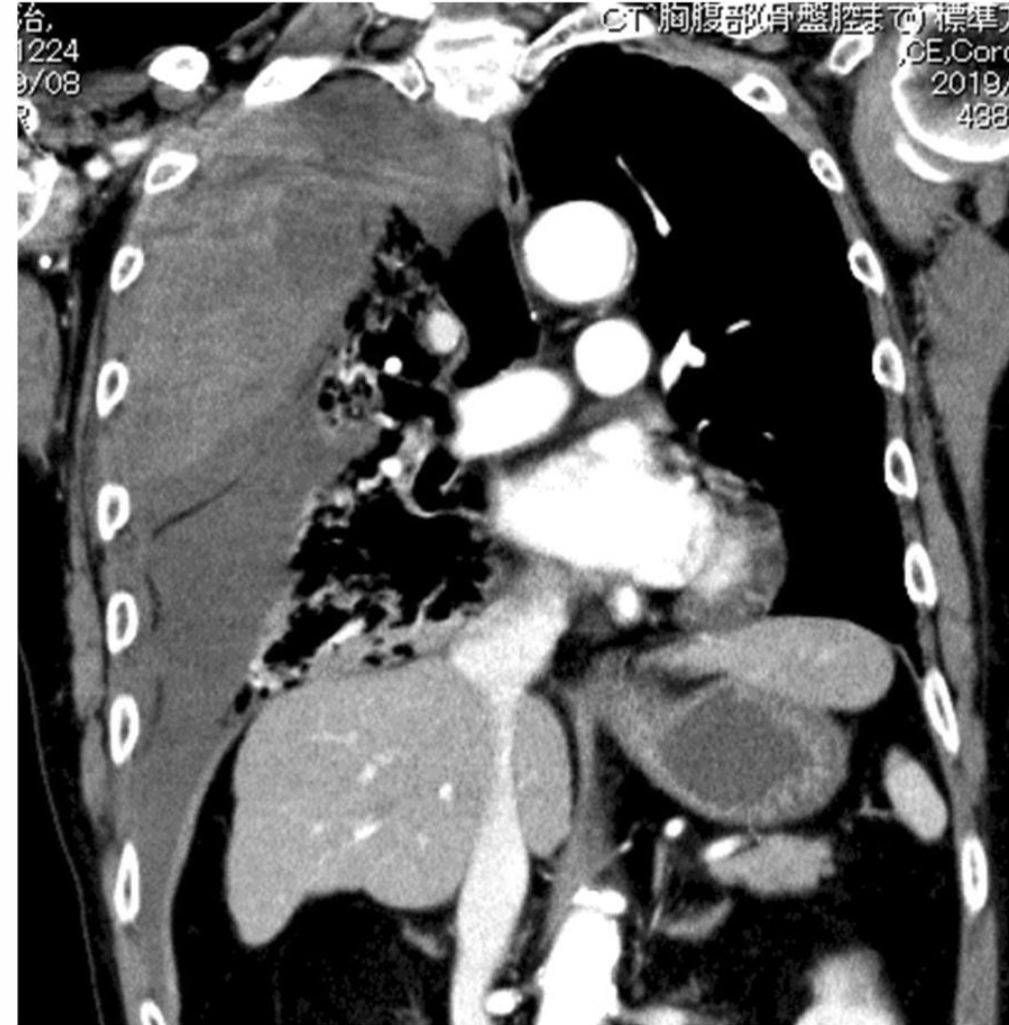
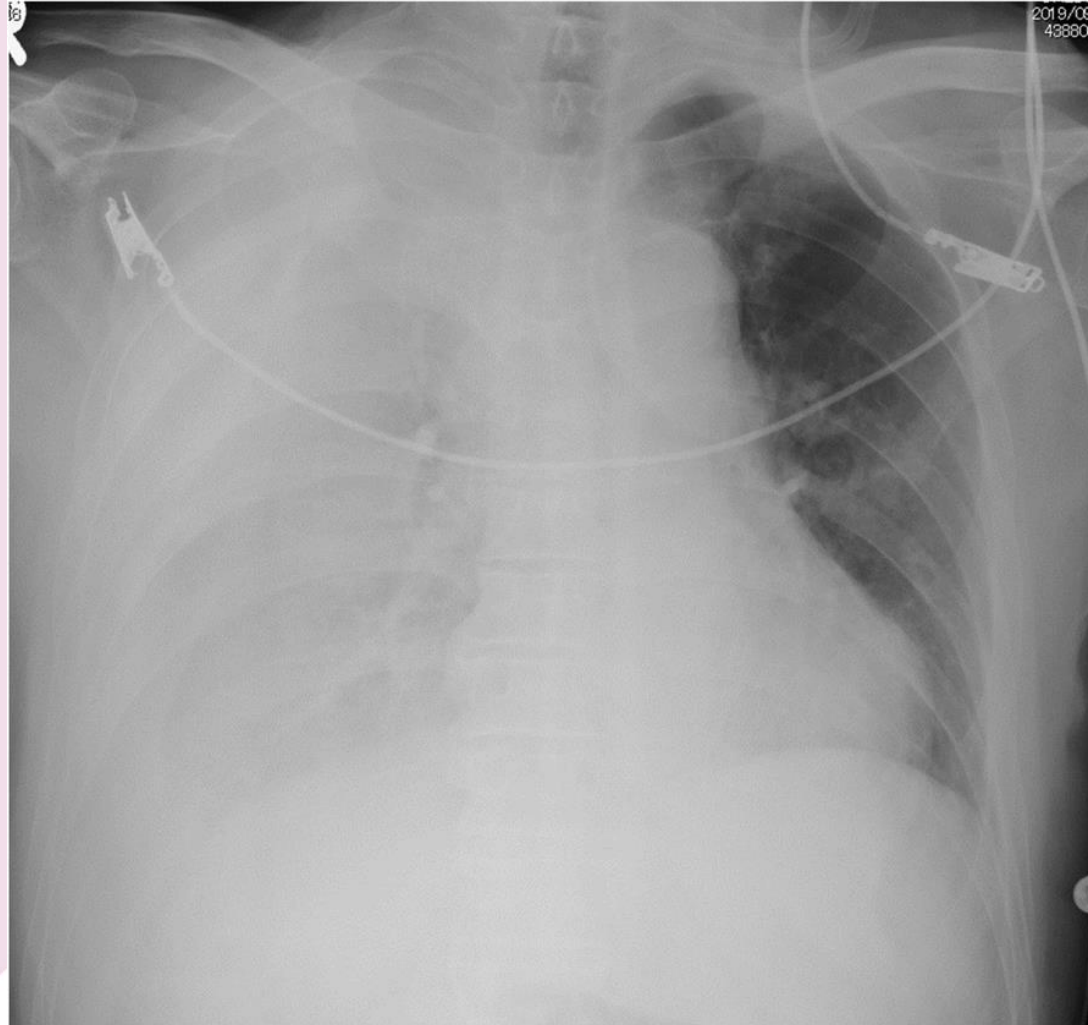
Case #3

- 78y/M, no apparent history of trauma
- Right shoulder pain and disturbance of consciousness
- Antiplatelet agent

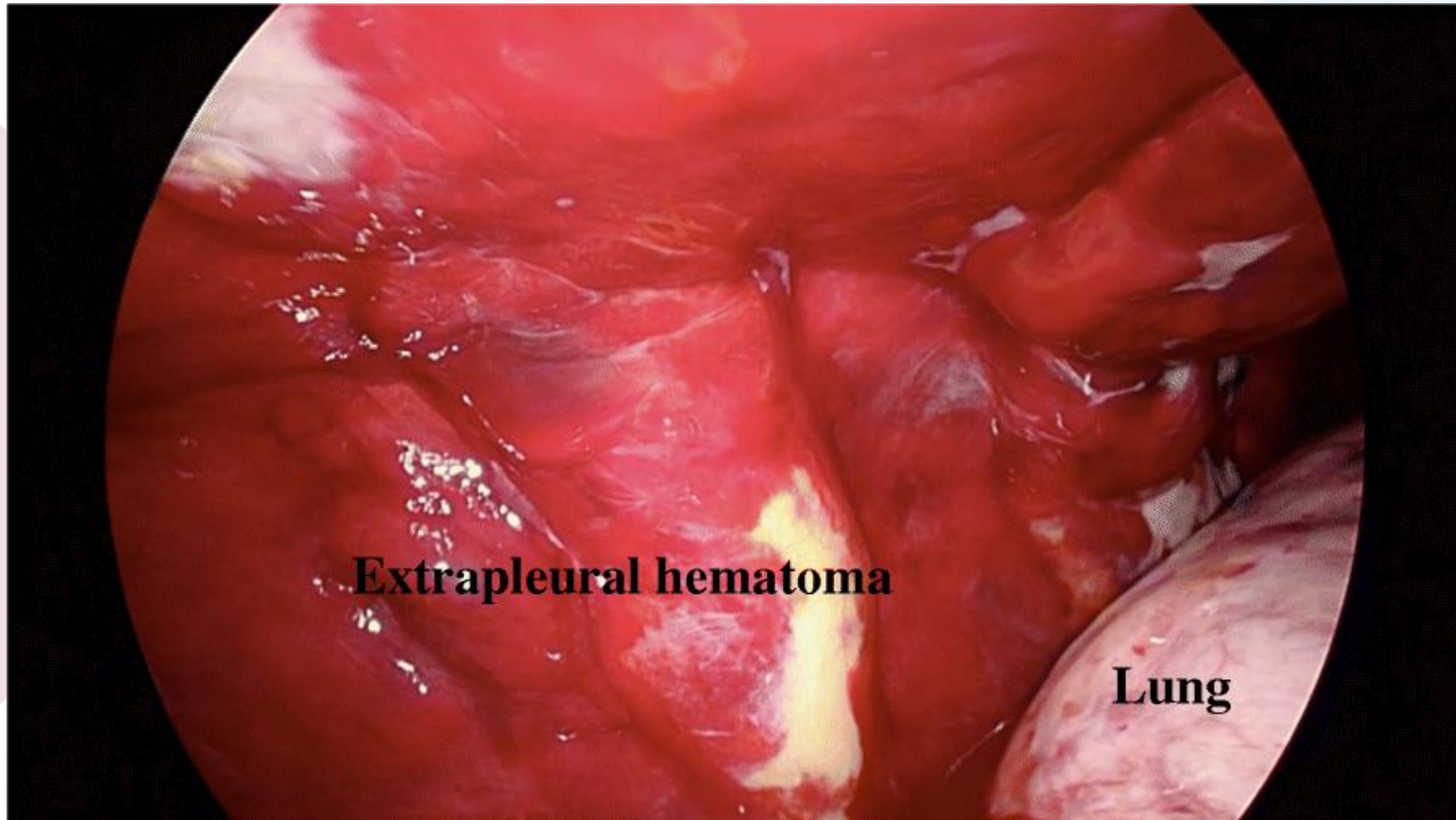
* Oka, S., Ono, K., Kajiyama, K. et al. Two extremely rare cases of extrapleural hematoma. surg case rep 5, 200 (2019)



Case #3



Case #3



K-Case #1

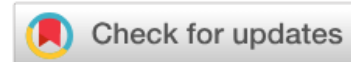Case Report

Traumatic Extrapleural Hematoma Mimicking Hemothorax

Yong Seon Choi, M.D., Soon Jin Kim, M.D., Sang Woo Ryu, Seung Ku Kang

Journal of Trauma and Injury 2017;30(4):202-205. DOI: <https://doi.org/10.20408/jti.2017.30.4.202>

Published online: December 30, 2017



[Author information](#) ^ | [Article notes](#) v | [Copyright and License information](#) v

Department of Thoracic and Cardiovascular Surgery, Mokpo Hankook Hospital, Mokpo, Korea

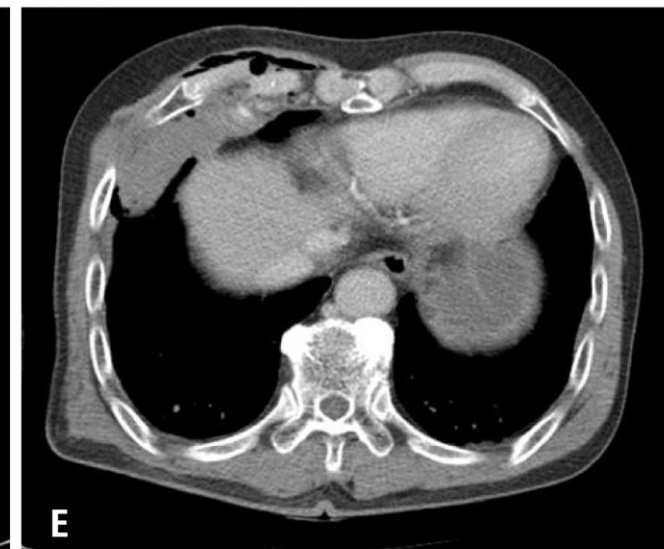
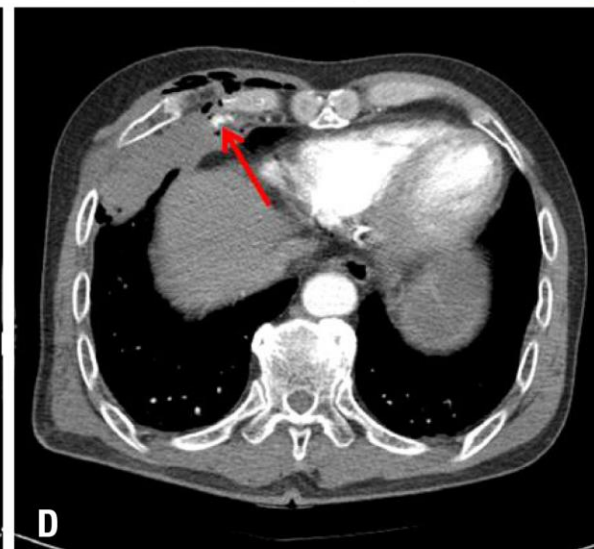
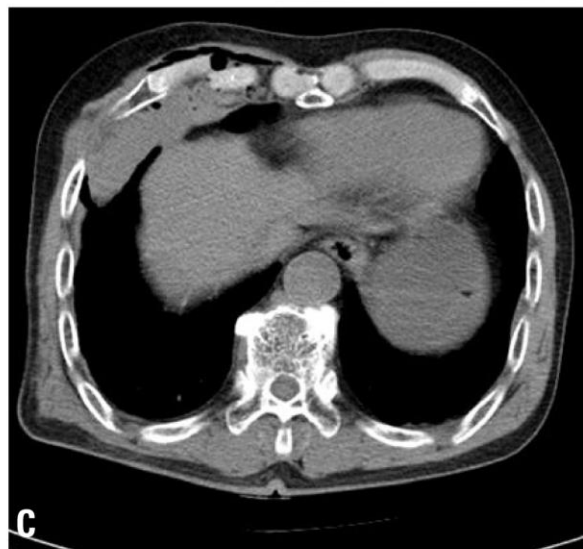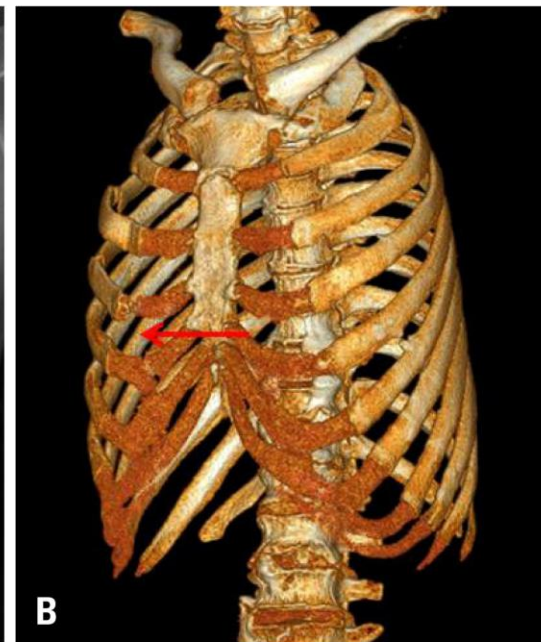
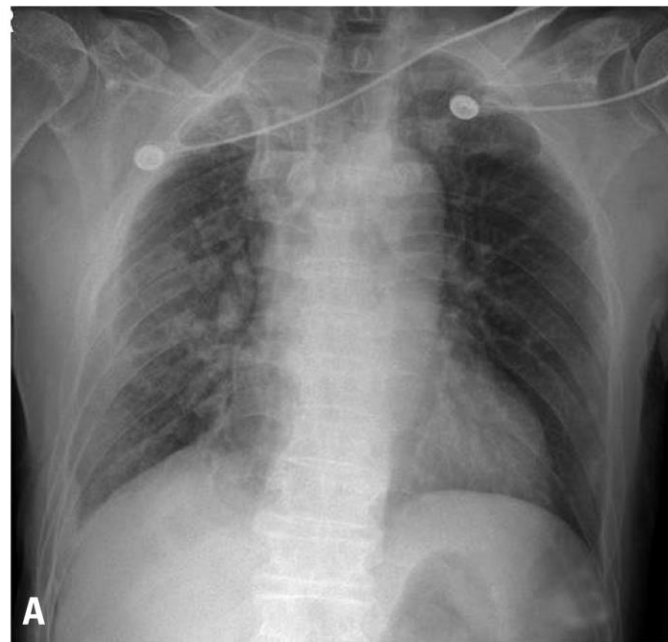
Correspondence to: Soon Jin Kim, M.D., Department of Thoracic and Cardiovascular Surgery, Mokpo Hankook Hospital, 483 Yeongsan-ro, Mokpo 58643, Korea, Tel: +82-61-270-5574, Fax: +82-61-277-0199, E-mail : innocent-blood@hanmail.net

K-Case #1

- 70y/M, blunt trauma
 - Right hemothorax with contrast-media leakage
 - Subcutaneous emphysema and multiple rib fractures (right 2nd–7th)
- OR to control the chest wall bleeding and reduce thoracic instability



K-Case #1

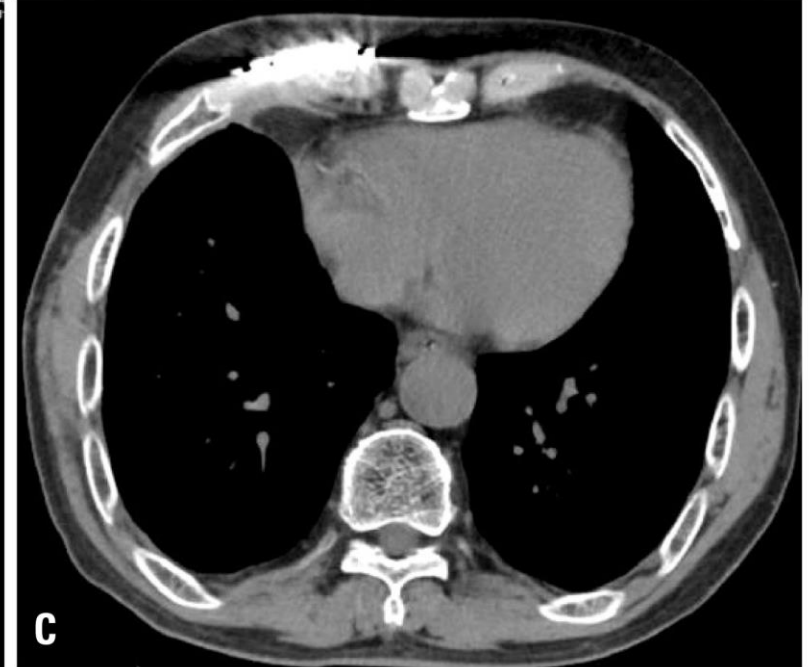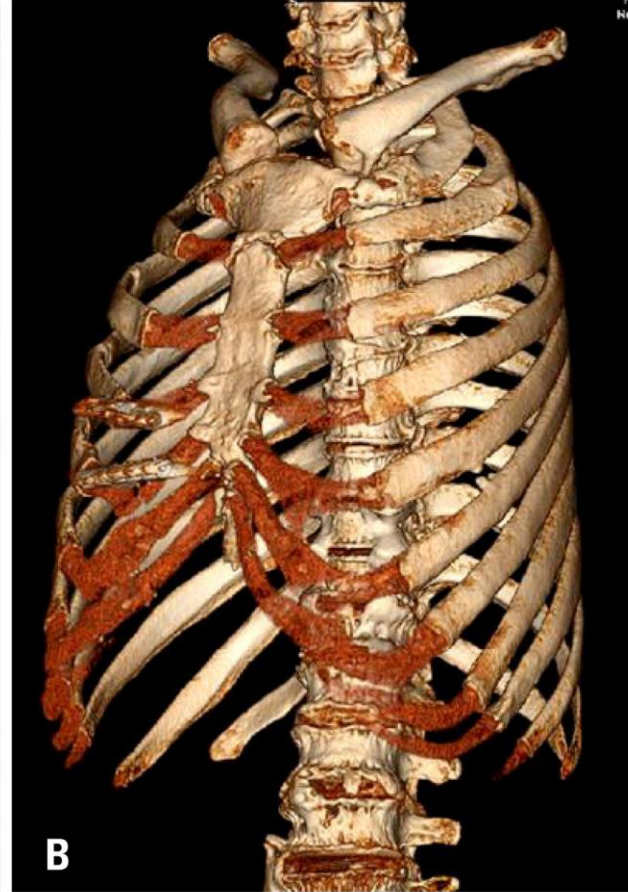

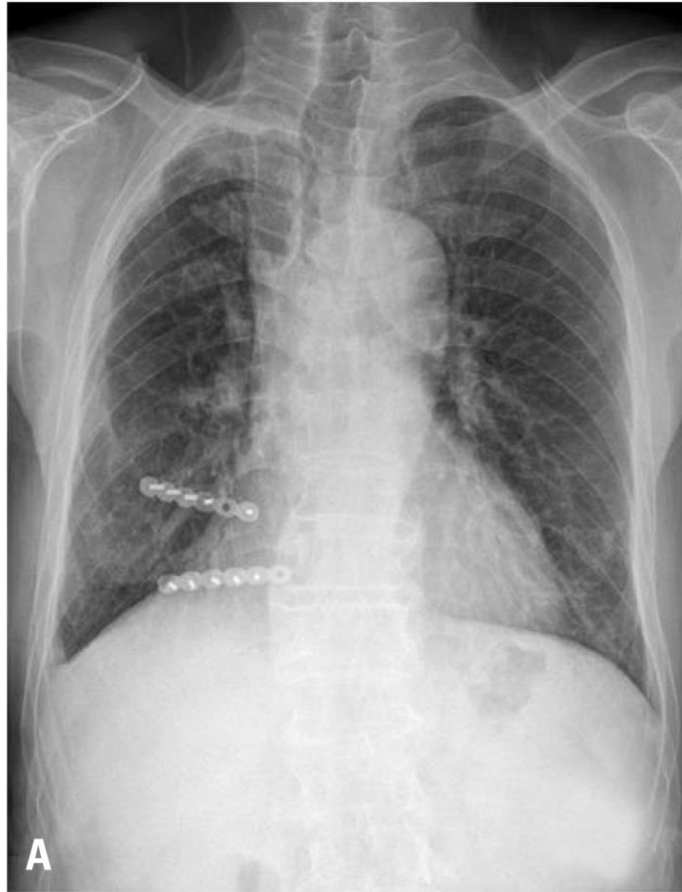
K-Case #1

- A right anterolateral thoracotomy was made at the fourth intercostal space.
- The fractured 5th rib was elevated and a moderately sized hematoma was subsequently identified and gently evacuated.
- The extrapleural space was then exposed and the parietal pleura's dense adhesions were detected
- Bleeding from intercostal artery was controlled with electrocautery.
- The fractured 4th and 5th ribs were reduced and plate fixation was performed.
- A 24 French chest tube was inserted through a separate incision.



K-Case #1



K-Case #2

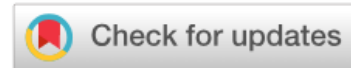Case Report

Large Focal Extrapleural Hematoma of Chest Wall: A Case Report

Hohyoung Lee, M.D., Sung Ho Han, M.D., Min Koo Lee, M.D., Ph.D., Oh Sang Kwon, M.D., Kyoung Hwan Kim, M.D., Jung Suk Kim, M.D., Soon-Ho Chon, M.D., Ph.D., Sung Ho Shinn, M.D., Ph.D.

Journal of Trauma and Injury 2019;32(2):115-117. DOI: <https://doi.org/10.20408/jti.2019.001>

Published online: June 30, 2019



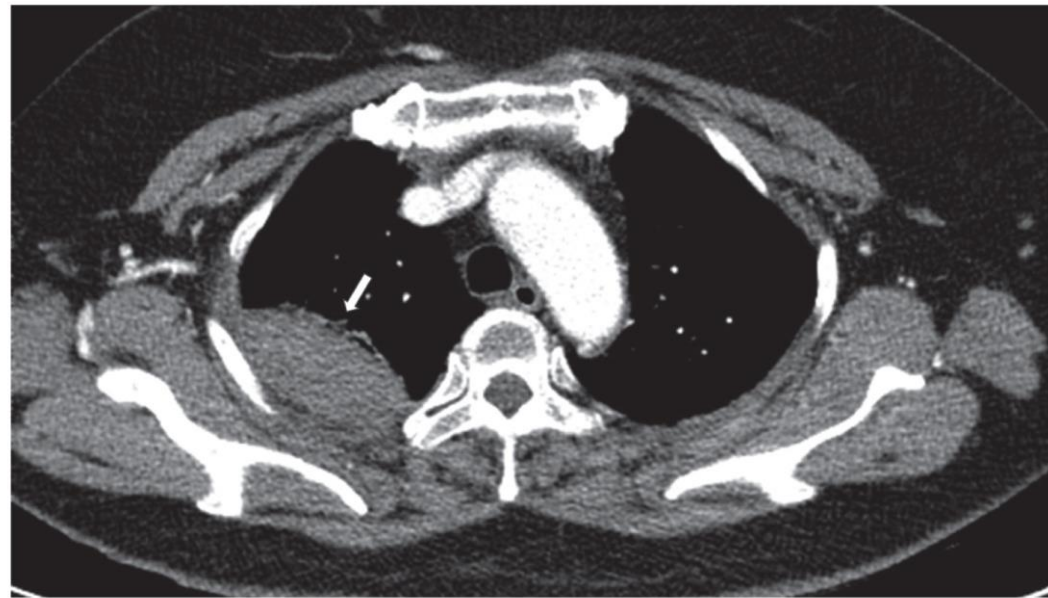
[Author information](#) ^ | [Article notes](#) v | [Copyright and License information](#) v

Departments of Trauma Surgery and Thoracic and Cardiovascular Surgery, Cheju Halla Hospital, Jeju, Korea

Correspondence to Soon-Ho Chon, M.D., Ph.D. Departments of Trauma Surgery and Thoracic and Cardiovascular Surgery, Cheju Halla Hospital, 65 Doryeong-ro, Jeju 63127, Korea, Tel: +82-64-740-5039, Fax: +82-64-743-3110, E-mail: sh.chon@hotmail.com

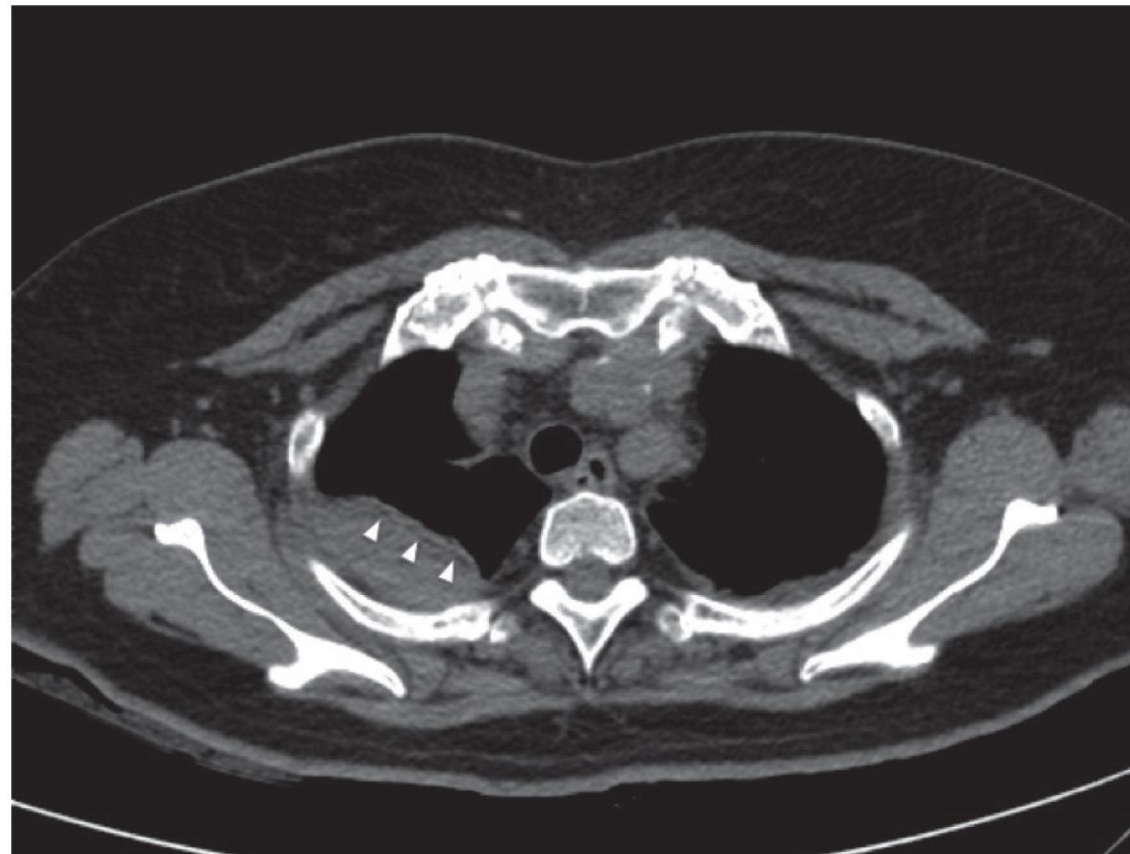
K-Case #2

- 63y/F, fall down
 - MRF, Rt. 3rd to 5th ribs, sternum fracture and right hemothorax
- Pig-tail drainage was done on the 4th hospital day

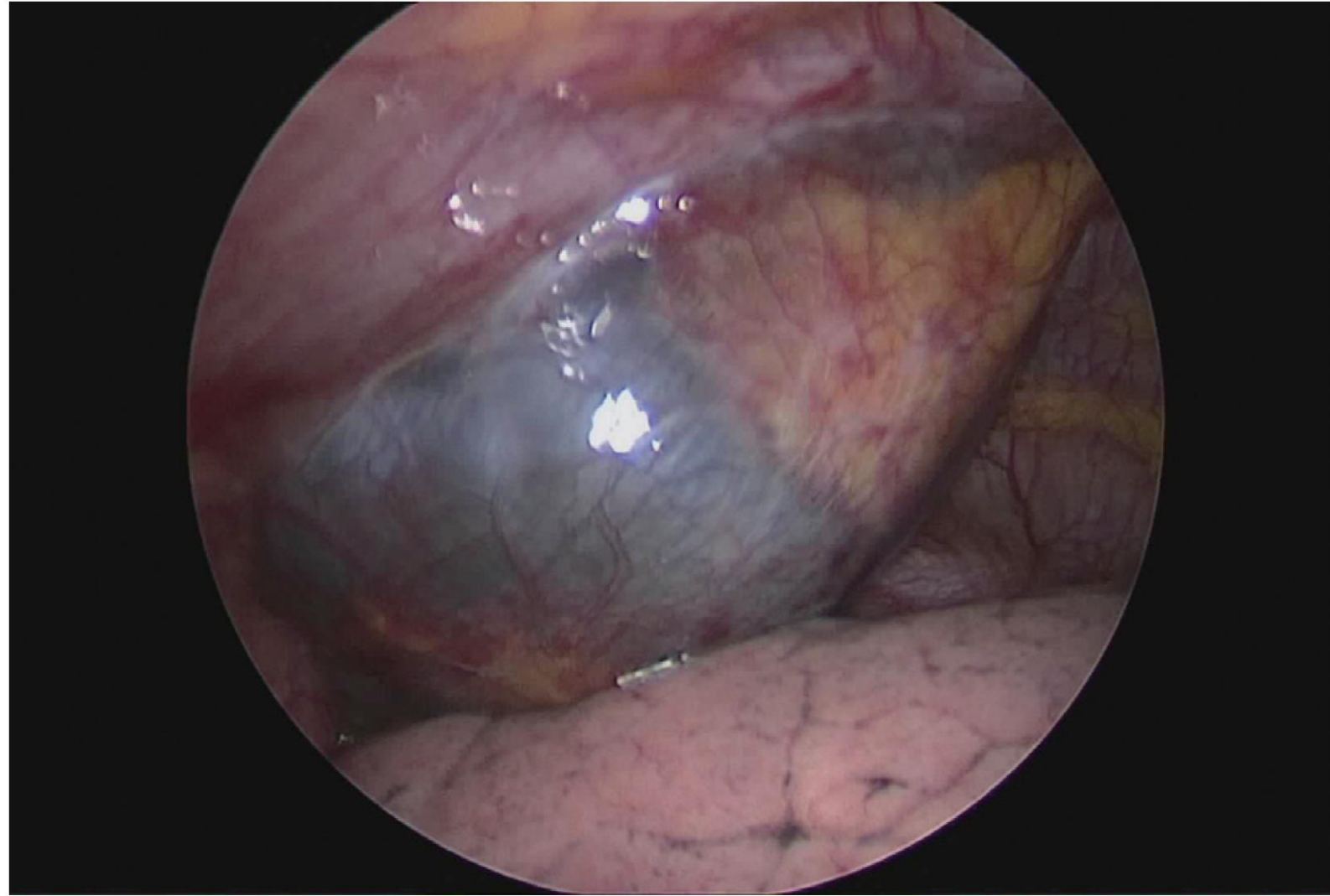


K-Case #2

- The images presented remaining local hematoma
→ VATS procedure was scheduled on the 11th hospital day with supposed diagnosis of loculated effusion or impending empyema



K-Case #2



Conclusion

- Don't underestimate EPH
- Be aware of the patient's underlying medical conditions
- Remember the characteristic findings on CT
- If a bleeding focus is seen on CT, embolization may be considered
- Decide on a surgical approach based on the size and location of the EPH





국립중앙의료원

national medical center



서울권역외상센터

국립중앙의료원

national medical center

