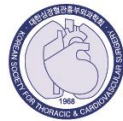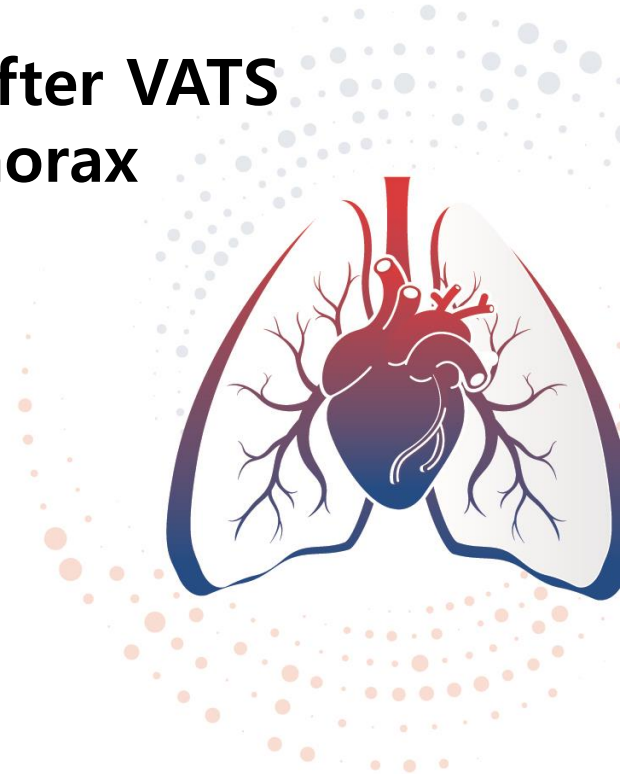


2023 대한심장혈관흉부외과학회

제55차 추계학술대회 & APELSO 2023

2023. 11. 02 (Thu) - 11. 04 (Sat), 그랜드 인터컨티넨탈 파르나스 서울

**Pleural coverage with a PGA sheet and fibrin glue after VATS
bullectomy for primary spontaneous pneumothorax**



- Pleural coverage of the stapled line is performed using various reinforcing materials to prevent prolonged air leak and reduce recurrence after VATS bullectomy.
- However, the most effective pleural coverage method has not been established.
- This study aimed to investigate the effectiveness of pleural coverage using a PGA sheet and fibrin glue.

- From 2012 to 2021, the medical records of 102 patients aged < 40 years who underwent VATS bullectomy for primary spontaneous pneumothorax at our hospital were retrospectively reviewed.
- Pleural coverage was divided into a group using only fibrin glue (Group A) and a group using PGA sheet and fibrin glue (Group B).
- Postoperative outcomes and recurrence were comparatively analyzed.

- There were 87 males and 15 females among the total patients, and their median age was 19 years. Pneumothorax occurred in 46 cases on the left side and 56 cases on the right side. The average postoperative chest tube duration was 2.58 ± 2.82 days, and hospital stay was 3.58 ± 2.86 days.
- During the follow-up period, recurrence was confirmed in 10 patients: three patients each were resolved by observation, oxygen inhalation, and closed thoracostomy, and one patient required reoperation.
- According to the comparative analysis between the two groups, the chest tube duration (2.02 ± 1.94 vs. 3.26 ± 3.51 days; $p = 0.036$) and hospital stay (3.02 ± 2.03 vs. 4.26 ± 3.53 days; $p = 0.038$) were significantly shorter, and the incidence of prolonged air leak (> 4 days) was significantly lower (5.4% vs. 23.9%; $p = 0.009$) in Group B.
- The postoperative recurrence rate was lower in Group B (7.1%) than in Group A (13.0%), although it was not statistically significant.

- Performing pleural coverage of the stapled line using a PGA sheet and fibrin glue after VATS bullectomy with primary spontaneous pneumothorax is effective and is expected to lower the recurrence rate.
- However, additional data is necessary to confirm this.